



## Management of Canine Spinal Cord Transmissible Venereal Tumor

Neeranoot Detcharoenyos<sup>1</sup>, Kamonchanok Silmaneephan<sup>1</sup>, Nuntapop Lertchaiprasert<sup>1</sup> and Soontaree Petchdee<sup>2\*</sup>

<sup>1</sup>Kasetsart University Veterinary Teaching Hospital, Faculty of Veterinary Medicine, Kasetsart University, Kamphaeng Saen, Nakorn Pathom, Thailand

<sup>2</sup>Department of Large Animal and Wildlife Clinical Science, Faculty of Veterinary Medicine, Kasetsart University, Kamphaeng Saen Nakorn Pathom, Thailand

\*Corresponding author: fvetstr@ku.ac.th

### ABSTRACT

Transmissible venereal tumor (TVT) is the most common malignancy in dogs. This is a rare case report described in the literature of extragenital transmissible venereal tumors. A 5-year-old male crossbred dog was brought to Kasetsart Veterinary Teaching Hospital, Kamphaeng Saen, presenting with subacute progression post-paresis within five days. A cauliflower-like mass with bloody discharge was found on the penis. The magnetic resonance imaging (MRI) showed an intradural-extramedullary mass on the right side of the T10-11 area. A right hemilaminectomy of T10-T11 and durotomy were performed to excise the abnormal mass. The biopsy result revealed a round cell tumor suggestive of a transmissible venereal tumor. After the operation for 84 days, the dog entirely recovered without recurrent signs. We provide practical information on the diagnosis and clinical management of canine spinal cord TVTs in a dog.

**Keywords:** Dog, Spinal cord tumor, Transmissible venereal tumor.

### Article History

Article # 24-711

Received: 20-Jul-24

Revised: 03-Aug-24

Accepted: 23-Aug-24

Online First: 23-Sep-24

### INTRODUCTION

The canine transmissible venereal tumor (TVT) is a round cell tumor that has no sexual, breed, or age predisposition, with external genital organ occurrence being the most frequent (Ignatenko et al., 2020; Pimentel et al., 2021; Solano-Gallego and Masserdotti, 2023). TVT can be transmitted by the implantation of viable tumor cells in mucous membranes (Mac-Ewen, 2001). Metastasis is uncommon in this type of neoplasm, especially in puppies and immunosuppressed animals (Hsiao et al., 2002; Mukaratirwa and Gruys, 2003). Extragenital manifestations have also been reported, such as those in the skin, brain, eye, liver, spleen, testis, muscle, and inguinal lymph nodes (Park et al., 2006; Groth et al., 2021; Faro et al., 2023). The diagnosis of spinal cord TVT typically involves a combination of physical examination, imaging studies such as radiography or MRI, and biopsy of the tumor tissue. Treatment options may include surgery to remove the tumor, chemotherapy, radiation therapy, or a combination of these modalities (Abeka, 2019; Duzanski et

al., 2023; José-López, 2023). The complete surgical excision of localized tumors without metastatic involvement is associated with the highest probability of cure. However, complete surgical excision often cannot be achieved because of the anatomic location, and contamination of the surgical site with TVT cells is also a source of recurrence (Boscos & Verwerdis, 2004). Therefore, chemotherapy with 0.5 mg/m<sup>2</sup> IV vincristine sulfate once a week for 3–6 cycles is effective (Johnson, 2005). TVT of the spinal cord is extremely rare. However, the spinal TVT may be one of the further differential diagnoses in case of neurological deficit associated with spinal cord compression. This case report provides its uncommon presentation and successful treatment by surgical excision and ongoing chemotherapy.

### Case Description

A 5-year-old male crossbred dog weighing 25kg was referred to Kasetsart Veterinary Teaching Hospital Kamphaeng Saen, Thailand. The dog had subacute progression post - paresis within the 5 days without

**Cite this Article as:** Detcharoenyos N, Silmaneephan K, Lertchaiprasert N and Petchdee S, 2024. Management of canine spinal cord transmissible venereal tumor. International Journal of Agriculture and Biosciences 13(3): 439-443. <https://doi.org/10.47278/ijab/2024.144>



A Publication of Unique Scientific Publishers

improvement after nonsteroidal anti-inflammatory drugs (NSAIDs) administration for 3 days. On neurological examination, the dog presented post-paretic grade IV, hyperreflexia of the hindlimbs, nociceptive reflexes was still intact, absented of proprioceptive responses, pained at the T10–L1 area, and there was a cutaneous trunci reflex cutoff at the T11 vertebra. The urinary incontinence was observed. A cauliflower-like mass with a bloody discharge was found on the penis. Other vital signs were normal. The myelopathy of the T3–L3 lesion was indicated.

### Clinical Evaluation and Management

The hematology and serum biochemistry were performed routinely, as shown in Table 1. Thrombocytopenia was detected on Day 1. A radiographic image of the thoracolumbar spine was unremarkable, as

shown in Fig. 1. For the further diagnosis of the T3–L3 lesion, an MRI scan with 1.5 tesla and contrast media injection was performed. The MRI showed an intradural-extramedullary mass on the right side of the T10–11 area with severe compression of the spinal cord (Fig. 2). Cerebrospinal fluid (CSF) analysis revealed an increased total nucleated cell count (TNCC = 1 cells/ $\mu\text{L}$ ), but TVT cells were not detected. The surgical removal of the spinal tumor was recommended.

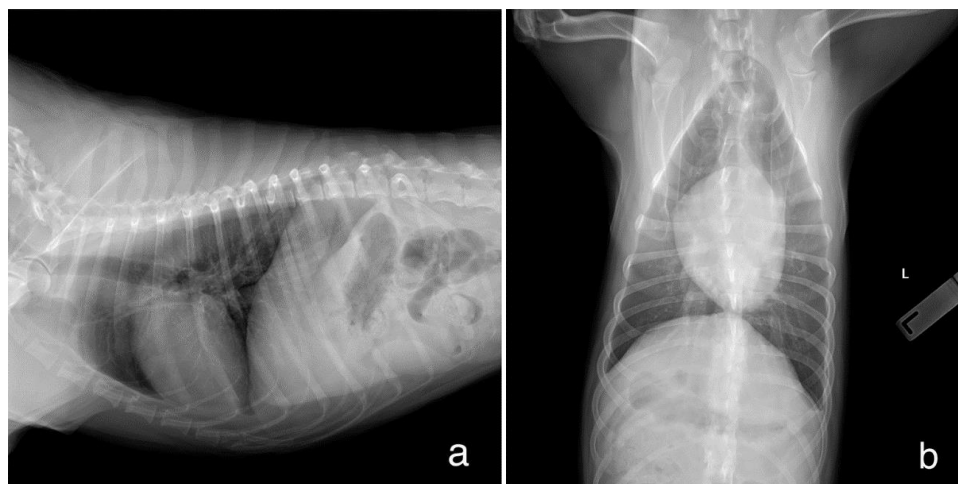
The dog was premedicated with diazepam 0.25mg/kg/IV, induction with propofol 4mg/kg/IV, intubated, and maintained with isoflurane 1 L/min in oxygen passing through a circular breathing system for anesthesia. The electrocardiogram, blood pressure, capnography, oxygen saturation, and body temperature were monitored closely during anesthesia.

The intraoperative picture is presented in Fig. 3.

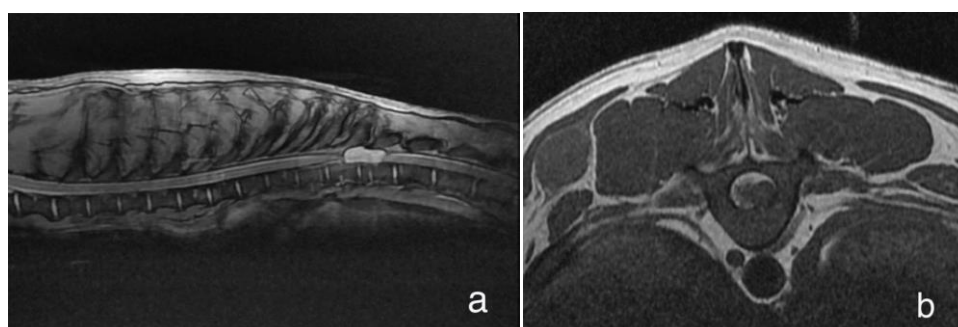
**Table 1:** Blood profiles

	Reference range	Result day1	Result day23	Result day30	Result day84
HCT (%)	30-35	46.1	47.9	47.1	41.2
RBC( $\times 10^6/\mu\text{L}$ )	5-9	7.51	7.86	7.8	6.5
Hb(gm%)	12-18	15.8	16.3	16.6	14.1
MCV (fL)	60-70	61.4	60.9	60.4	63.4
MCHC (gm%)	32-36	34.3	34	35.2	34.2
WBC ( $\times 10^3/\mu\text{L}$ )	6-17	12.58	5.05	13.24	13.47
Band neutrophil ( $\times 10^3/\mu\text{L}$ )	0-0.3	0	0	0	0
Segmented neutrophil ( $\times 10^3/\mu\text{L}$ )	3-11.5	6.87	2.58	10.44	9.52
Lymphocyte ( $\times 10^3/\mu\text{L}$ )	1-4.8	3.64	1.42	1.59	1.6
Monocyte ( $\times 10^3/\mu\text{L}$ )	0.15-1.35	0.88	0.76	0.8	0.59
Eosinophil ( $\times 10^3/\mu\text{L}$ )	0.1-1.25	1.18	0.28	0.39	1.74
Platelet ( $\times 10^3/\mu\text{L}$ )	200-900	108	453	278	291
Protein (refract) (gm%)	5-7.5	8	8	7.6	8.2
Creatinine (mg%)	<1.8	1.19	1.17	1.03	1.22
BUN (mg%)	<346	17.3	14.3	18.3	17.9
ALT (U/L)	<89	18	27	23	17

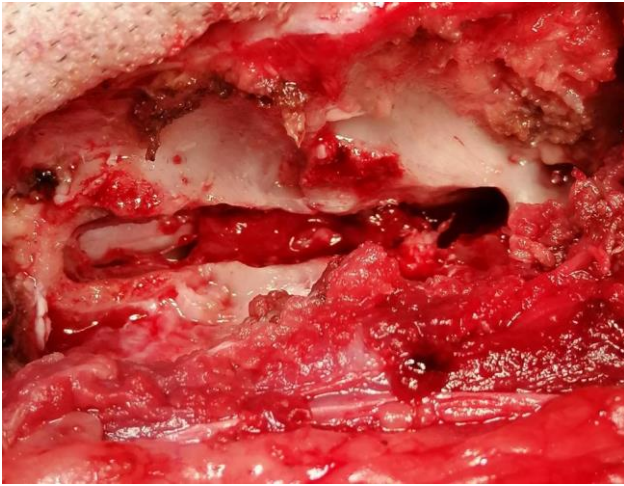
HCT = hematocrit; RBC = Red blood cell; HGB = hemoglobin; MCV = Mean corpuscular volume; MCHC = Mean corpuscular hemoglobin concentration; WBC = White blood cell



**Fig. 1:** Radiograph of thoracic, lateral view (a) and ventrodorsal view (b).



**Fig. 2:** T2-weighted sagittal (a) and transverse (b) MRI showing mass at T10-11 with severely compressed spinal cord.



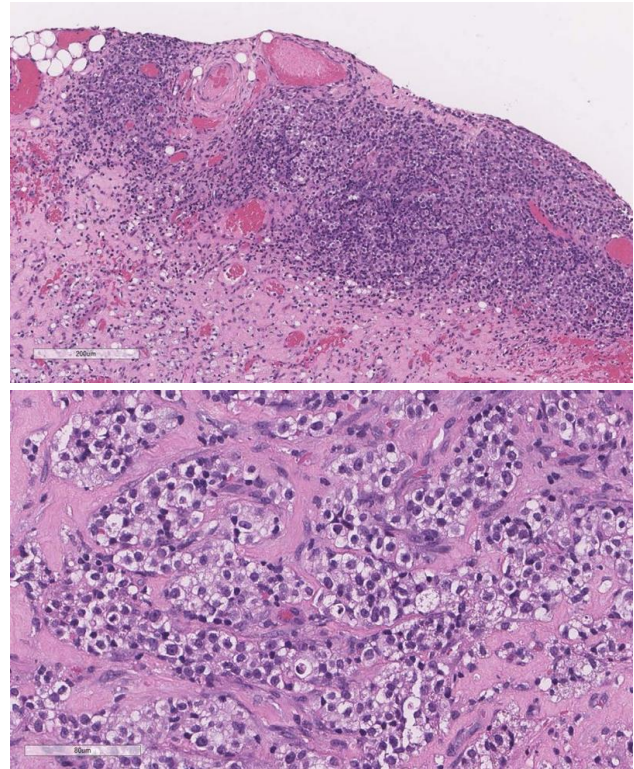
**Fig. 3:** Intraoperative view of pathological mass present at T10-11 area.

A right hemilaminectomy of T10-T11 and durotomy were performed to excise abnormal masses, and samples were collected for histological examination. After flushing with sterile saline, the defect was covered with an autologous fat graft. The 2-0 polyglycolide monofilament absorbable suture was used to close the muscle sheath via a cross-mattress pattern and the subcutaneous layer via a simple continuous pattern, respectively. The 2-0 nylon monofilament nonabsorbable suture was used to close the skin layer via a cross-mattress pattern. The total tumor was resected, approximately in size of 3x1 cm in diameter.

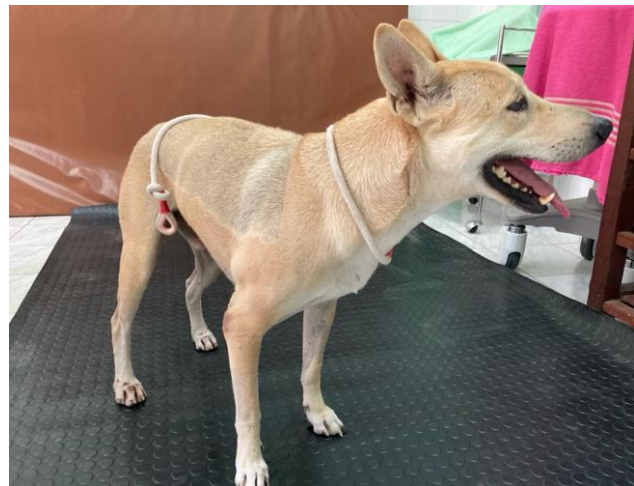The excised mass was sent for a histopathological diagnosis. The biopsy result presented a round cell tumor suggestive of an extragenital transmissible venereal tumor, as shown in Fig. 4. The cytological findings of the penile mass revealed many round cell tumors with a moderate amount of vacuolated cytoplasm and round to oval prominent nuclei, characteristic of TVTs.

For postoperative care, to control pain and inflammation, fentanyl 0.002mg/kg was administered intravenously every 4 hours, and carprofen 2.2mg/kg was administered subcutaneously every 12 hours. Amoxicillin-clavulanic acid 20mg/kg was administered intravenously every 8 hours to control infection. N-acetylcysteine 50mg/kg was also prescribed as an antioxidant supplement.

After surgery for 7 days, the dog presented partial weight-bearing, ambulatory paraparesis of bilateral hindlimbs, and the proprioceptive responses were improved (Fig. 5). There were no complications in the incision area. The 0.5mg/kg of prednisolone (sid), 10mg/kg of doxycycline (sid), and 5mg/kg of gabapentin (bid) were orally administered. Vincristine sulfate (0.75 mg/m<sup>2</sup>, IV, q 14 days) treatment was then initiated. A CBC profile was performed, and after one application of vincristine, leukopenia was observed (5,050  $\mu$ l), which was ascribed to bone marrow suppression due to the vincristine treatment. However, the leukopenia improved within 14 days. The penile and prepuce masses were not found after six applications of vincristine (Fig. 6). After surgery for 58 days, the neurological signs exhibited almost complete recovery.



**Fig. 4:** The microscopic finding presented a round cell tumor, suggesting an extragenital transmissible venereal tumor. Stain??; Magnification??

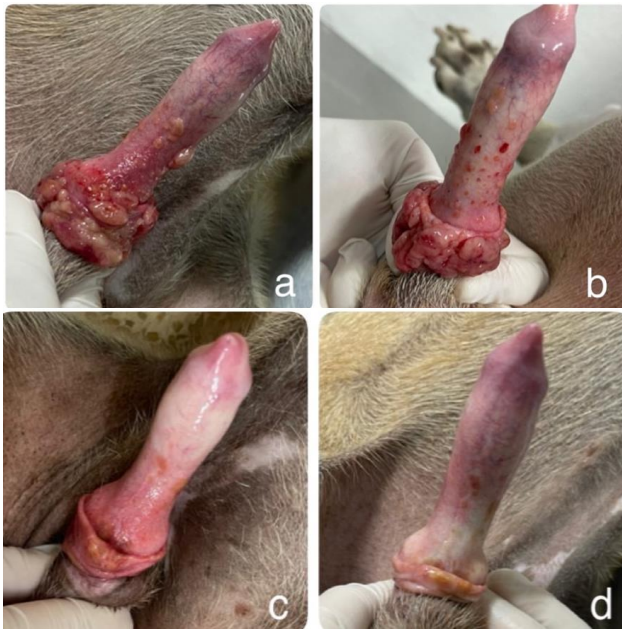

**Fig. 5:** On postoperative day 7, the dog presented bilateral hindlimbs, partial weight-bearing, and ambulatory paraparesis.

## RESULTS & DISCUSSION

Extragenital TVT is uncommon; it can occur in two ways. The first is natural implantation at wound sites (Withrow et al., 2012). The second is through metastasis when the primary organ is the genital organ (Ganguly et al., 2016), as in this patient. However, the main tissue affected is the regional lymph node. Cavitary organs can also be sites of metastasis and abdominal ultrasonography is recommended. The use of spinal cord TVT is rarely documented. In dogs, intradural-extramedullary tumors are usually nerve sheath tumors or meningiomas (Dewey & Costa, 2016). When TVT cells metastasize to the spinal cord, a variety of neurological symptoms and complications can occur. These may include weakness or





**Fig. 6:** Recovery of the cauliflower-like mass at the penis over 7 days (a), 23 days (b), 44 days (c), and 84 days (d)

paralysis, include weakness or paralysis, difficulty walking or standing, urine incontinence, and pain (Ferreira et al., 2000). However, neurological signs such as subacute progression post-paresis were observed in our study. Thyroid carcinomas, mammary tumors, prostatic adenocarcinomas, and hemangiosarcomas are the tumors that most frequently metastasize to the vertebrae (Lorenz et al., 2011). It is concluded that metastases can occur and that TVT should be included in the differential diagnosis of spinal cord neoplasms.

Total resection of the spinal cord tumor was performed in this patient. However, contamination of the surgical site with TVT cells is also a source of recurrence (Boscos & Ververidis, 2004), and complete surgical excision of the penile mass cannot be achieved because of the anatomic location. The most effective chemotherapy dose is 0.5 mg/m<sup>2</sup> IV vincristine sulfate once a week for 3–6 cycles (Johnson, 2005; Setthawongsin et al., 2019). In this patient, leukopenia was observed after one application of vincristine, which was attributed to bone marrow suppression due to the side effects of vincristine. Therefore, vincristine was applied every 2 weeks instead. The penile and prepuce masses improved after six applications of vincristine.

Lomustine is a chemotherapy agent that can cross the blood-brain barrier. However, this drug can cause hematologic events such as neutropenia, thrombocytopenia, and hepatopathy (Cunha et al., 2017). Lomustine therapy for vincristine-resistant TVT has also been reported (Duzanski et al., 2020). This drug was not applied to this patient because of the owner's decision.

Computed tomography (CT) and magnetic resonance imaging (MRI) are necessary to diagnose spinal cord TVT. The plain radiography could not provide enough information for the vertebral canal. MRI is the best method for central nervous system diagnoses, it could provide more details about the location and severity of the lesion.

A CT scan of the vertebral canal after completing therapy was not performed in this patient because of the cost of diagnosis. However, the patient's neurological signs were stable after 1 year.

### Conclusion

TVTs are the most common malignancy in dogs, they are rarely located on the spinal cord. Early detection and intervention are crucial for improving patient outcomes. The operation is necessary in cases of neural compression and pain. In this case, successful TVT management was achieved by laminectomy to remove the TVT mass and ongoing chemotherapy. The dog's clinical signs improved, and a recurrence was not detected one year after the operation.

### Acknowledgments

The authors are grateful to the owner and Kasetsart Veterinary Teaching Hospital Kamphaeng Saen, Thailand for providing the necessary facilities.

### Conflict of Interest

The authors declare that there is no conflict of interest.

### Author's Contribution

All the authors contributed to the manuscript. Neeranoot Detcharoenyos, Kamonchanok Silmaneephan, Nuntapop Lertchaiprasert and interpreted the results and Soontaree Petchdee drafted, critically revised, and approved a manuscript.

### REFERENCES

- Abeka, Y.T., (2019). Review on Canine Transmissible Venereal Tumor (CTVT). *Cancer Therapy & Oncology*, 14(4), 555895. <http://doi:10.19080/CTOIJ.2019.14.555895>
- Boscos, C., & Ververidis, H. (2004). Canine TVT Clinical findings, diagnosis and treatment. *Science Proceedings Wsava Fecava Hvms World Congress, Rhodes, Greece*, 2: 758-761.
- Cunha, S.C., Silva, F.B., Corgozinho, K.B., Silva, K.V., & Ferreira, A.M. (2017). Adverse Effects of Chemotherapy in Dogs. *World Veterinary Journal*, 7(3), 74-82.
- Duzanski, A. D. P., Feo, H. B., Montoya Flórez, L. M., Dinau, F. C., Paiva, B. R., Brandão, C. V. S., & Rocha, N. S. (2023). Fibrosis in canine transmissible venereal tumor after chemotherapy with vincristine. *Brazilian Journal of Veterinary Medicine*, 45, e000123. <https://doi.org/10.29374/2527-2179.bjvm000123>
- Groth, A., Silva, L. A. dos S., Martins, M. I. M., Fernandes, M. P., Greggi, J. R., Amaral, L. M. de S., Silva, V. W., Aguiar, A. de. & Bracarense, A. P. F. R. L. (2021). Transmissible venereal tumor in a dog's abdominal cavity: Uncommon report. *Research, Society and Development*, 10(8), e0110816429. <https://doi.org/10.33448/rsd-v10i8.16429>
- Dewey, C.W., & Costa, R.C. (2016). Myelopathies. In *Practical guide to canine and feline neurology*, 3rd Eds. John Wiley and Sons, New Jersey, pp. 371-379.
- Faro, T. A. S., & de Oliveira, E. H. C. (2023). Canine transmissible venereal tumor - From general to molecular characteristics: A review. *Animal Genetics*, 54(1), 82-89. <https://doi.org/10.1111/age.13260>
- Ferreira, A. J., Jaggy, A., Varejão, A. P., Ferreira, M. L., Correia, J. M., Mulas, J. M., Almeida, O., Oliveira, P., & Prada, J. (2000). Brain and ocular metastases from a transmissible venereal tumour in a dog. *The Journal of Small Animal Practice*, 41(4), 165-168. <https://doi.org/10.1111/j.1748-5827.2000.tb03187.x>
- Ganguly, B., Das, U., & Das, A. K. (2016). Canine transmissible venereal tumour: a review. *Veterinary and Comparative Oncology*, 14(1), 1-12. <https://doi.org/10.1111/vco.12060>
- Hsiao, Y. W., Liao, K. W., Hung, S. W., & Chu, R. M. (2002). Effect of tumor

- infiltrating lymphocytes on the expression of MHC molecules in canine transmissible venereal tumor cells. *Veterinary Immunology and Immunopathology*, 87(1-2), 19–27. [https://doi.org/10.1016/s0165-2427\(02\)00026-0](https://doi.org/10.1016/s0165-2427(02)00026-0)
- Ignatenko, N., Abramenko, I., Soto, S., Mueller, R., Boehm, T. M. S. A., Troedson, K., Fejos, C., & Hirschberger, J. (2020). Nasal transmissible venereal tumours in 12 dogs - a retrospective study. Nasales Sticker-Sarkom bei 12 Hundeneine retrospektive Studie. *Tierarztl Prax Ausg K Kleintiere Heimtiere*, 48(3), 164–170. <https://doi.org/10.1055/a-1152-3772>
- Johnson, C. (2005). Transmissible Venereal Tumor. In: Merck Veterinary Manual, 9<sup>th</sup> Ed, Edited by Cynthia M. Kahn. Merck and Co. Inc. Whitehouse Station, N. J, U.S.A. pp. 1165.
- Lorenz, M.D., Coates, J.R., and Kent, M. (2011). Pelvic Limb Paresis, Paralysis, or Ataxia. In *Handbook of Veterinary Neurology*, 5<sup>th</sup> edn, Saunders, Philadelphia, pp. 135-138.
- Mac-Ewen, E. (2001). Transmissible venereal tumor. In: Withrow S and MacEwen E (eds.), *Small Animal Clinical Oncology*. 3<sup>rd</sup> Edition, Saunders, Philadelphia, pp: 651-656.
- Mukaratirwa, S., & Gruys, E. (2003). Canine transmissible venereal tumour: cytogenetic origin, immunophenotype, and immunobiology. A review. *The Veterinary Quarterly*, 25(3), 101–111. <https://doi.org/10.1080/01652176.2003.9695151>
- Park, M. S., Kim, Y., Kang, M. S., Oh, S. Y., Cho, D. Y., Shin, N. S., & Kim, D. Y. (2006). Disseminated transmissible venereal tumor in a dog. *Journal of Veterinary Diagnostic Investigation*, 18(1), 130–133. <https://doi.org/10.1177/104063870601800123>
- Pimentel, P. A. B., Oliveira, C. S. F., & Horta, R. S. (2021). Epidemiological study of canine transmissible venereal tumor (CTVT) in Brazil, 2000–2020. *Preventive Veterinary Medicine*, 197, 105526. <https://doi.org/10.1016/j.prevetmed.2021.105526>
- José-López, R. (2023). Chemotherapy for the treatment of intracranial glioma in dogs. *Frontiers in Veterinary Science*, 10, 1273122. <https://doi.org/10.3389/fvets.2023.1273122>
- Setthawongsin, C., Teewasutrakul, P., Tangkawattana, S., Techangamsuwan, S., & Rungsipipat, A. (2019). Conventional-Vincristine Sulfate vs. Modified Protocol of Vincristine Sulfate and L-Asparaginase in Canine Transmissible Venereal Tumor. *Frontiers in Veterinary Science*, 6, 300. <https://doi.org/10.3389/fvets.2019.00300>
- Solano-Gallego, L. and Masserdotti, C. (2023). Reproductive system. In Raskin RE, Meyer DJ, and Boes KM. (Eds.). *Canine and feline cytopathology: a color atlas and interpretation guide* 4 Ed, Elsevier, Rio de Janeiro, pp: 1934–1939.
- Withrow, S.J., Vail, D.M., and Page, R.L. (2012). *Small animal clinical oncology*. Amsterdam, Holanda: Elsevier Health Sciences.